

F. PATRICK MCKEGNEY*

Yale University School of Medicine

**DIENCEPHALIC PROJECTIONS OF THE MIDLINE AND
INTRALAMINAR NUCLEI IN THE CAT******INTRODUCTION**

Since 1942, when Morison and Dempsey¹ first published the finding that stimulation of certain subcortical structures in the region of the internal medullary lamina resulted in widely distributed "rhythmically recurrent cortical potentials," there has been a steadily increasing interest in the physiological and anatomical parameters of this so-called "recruiting response."

Subsequent investigations by Jasper² and by Starzl and Magoun³ bore out, in general, the initial results of Morison and Dempsey but differed to a certain degree as to which cortical areas were affected and which subcortical structures, when stimulated, elicited the "recruiting response." The group of subcortical structures includes, according to most investigators, the midline and intralaminar nuclei, the centrum medianum, the anterior nucleus, and the anterior portions of the reticular complex of the thalamus. However, cortical activation has also been reported by some authors upon stimulation of the n. ventralis anterior,⁴ n. medialis dorsalis,¹ n. reuniens,⁵ n. parafascicularis,⁶ n. postero-lateralis,⁷ and the pulvinar.⁸

It has been postulated that the nuclei from which recruiting phenomenon can be elicited are the diencephalic components of a "central activating system"^{9,†} or "centrencephalic system"^{10,‡} which would, by modulating all

* Fourth-year medical student.

** The material here presented is taken from a thesis submitted to the Faculty of the School of Medicine in partial fulfillment of the requirements for the degree of Doctor of Medicine in 1958.

This work was supported in part by two James Hudson Brown Summer Fellowships in 1956 and 1957 and in part by a research grant from the United States Public Health Service to Dr. Karl H. Pribram, Institute of Living, Hartford, Connecticut.

† The "central activating system" is defined by Magoun as being composed of the brain stem reticular formation, tegmentum, subthalamus, dorsal hypothalamus, and the ventro-medial thalamus. All of these structures possess the common characteristic of producing cortical desynchronization upon stimulation.¹²

‡ The "centrencephalic system" is described by Penfield as "an area of the brain, separate from the motor and sensory cortex, in which the highest level of functional integration is to be found . . . a ganglionic area in which . . . those nervous mechanisms are to be found which are prerequisite to the existence of the intellectual activity and prerequisite to the initiation of the patterned stream of efferent impulses that produce the planned action of the conscious man. . . . The intralaminar systems of the thalamus and the reticular formation of the brain stem and the non-specific projection systems which have widespread connections with the cortex of both sides satisfy the definition [of a 'centrencephalic system']."¹⁰

Received for publication April 15, 1958.

cortical activity, perhaps serve as the "neural substratum of consciousness" of Hughlings Jackson.*

The delineation of the neural pathways by which these structures so modify cortical activity, and thus behavior, is obviously an important one for an understanding of perceptual and learning processes and even mental illness. However, anatomical investigations of this region have lagged far behind the physiological studies.

Recent work has variously involved both basal ganglia and anterior rhinencephalon as possible routes of transmission of such diencephalic-mesencephalic influence on the isocortex. But very few studies have been designed to resolve the apparent discrepancies that have been reported. This study, therefore, was undertaken in an attempt to decide, by means of well-localized, superficial lesions of anterior rhinencephalic cortex, whether or not projections to this area from the midline and intralaminar nuclei do indeed exist.

MATERIALS AND METHODS

Surgical Procedures

Six cats were operated upon under Nembutal anesthesia. The left zygomatic arch and left temporal bone were removed, the dura opened and the brain retracted to reveal the left orbital surface. A sub-pial removal of prepyriform cortex was accomplished with a #19-gauge needle sucker. The dura was closed, the temporal muscle was sewn over the bony defect, and the skin closed in layers.

Anatomical Procedures

The animals were sacrificed 8 weeks after operation. Fixation was initiated by transcardial perfusion with saline, followed by 10 per cent formalin, and the brains subsequently stored in 10 per cent formalin for 1 week. They were then dehydrated in increasingly concentrated alcohol solutions, infused with 2 per cent, 5 per cent, and 10 per cent solutions of nitrocellulose and finally imbedded in 20 per cent nitrocellulose. Blocks were stored in 70 per cent alcohol until sectioned. Sections were cut of 50-micra thickness and were stained at 250-micra intervals, with the exception of those through the thalamus, which were stained at 100-micra intervals.

Tracings of sections at 1 mm. intervals were used in reconstructing and plotting the outlines of the orbital surface, the principal fissures and the lesion on graph paper. Tracings of the thalamic nuclei were made at .3 mm. intervals and the degeneration was analyzed by visual inspection and plotted. Criteria of degeneration in the thalamus were cell loss and glial reaction. No attempt was made to measure precisely the amount of cell loss.

RESULTS

The six brains can be conveniently divided into two groups: the first four ablations performed comprise the first group; the last two ablations, the second.

First Group

Cat ABLE: The lesion was limited to the left hemisphere and had as its bounds: laterally, the rhinal fissure; anteriorly, the posterior orbital gyrus proreus; posteriorly, the tip of the pyriform lobe; medially, the orbito-frontal and antero-limbic cortex. The ablation removed most of the

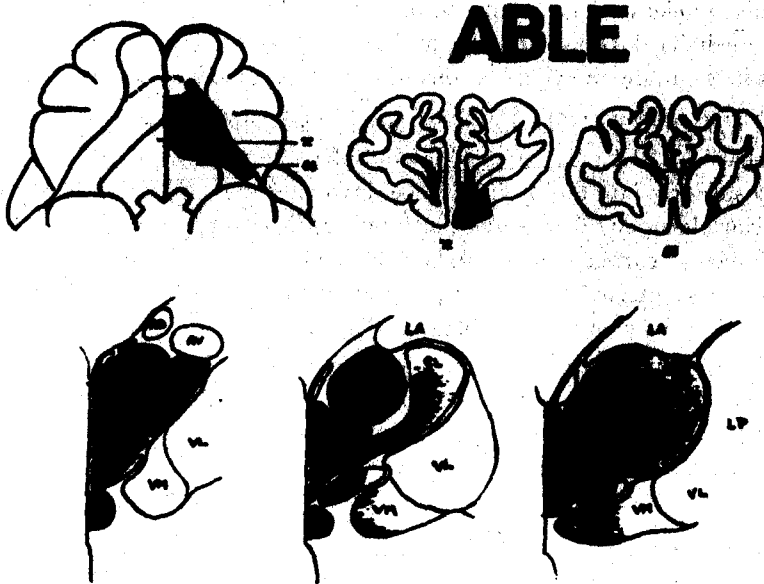


PLATE 1.

PLATES 1-4. Schematic drawings of the lesions and thalamic degeneration in all animals, including a composite drawing of the first group of animals (Plate 3). On Plate 3, the dotted area represents the cortical and subcortical structures involved by at least one lesion. The solid black areas show only the area common to all the lesions in the first group of animals and only the area of thalamic degeneration found in all animals of this group.

The thalamic nuclear delineation is based upon the atlas of V. Jimenez-Castellanos (*J. comp. Neurol.*, 1949, 91, 307-330).

Abbreviations are as follows:

- AD — n. antero dorsalis
- AV — n. antero ventralis
- CL — n. centralis lateralis
- CM — n. centralis medialis
- LA — n. lateralis anterior
- LP — n. lateralis posterior
- MD — n. medialis dorsalis
- PC — n. paracentralis
- RE — n. reuniens
- RH — n. rhomboidialis
- SM — n. submedius
- VL — n. ventralis lateralis
- VM — n. ventralis medialis

anterior olfactory tubercle, but none of the posterior tubercle and most of the prepyriform cortex. In depth, the most inferior tip of the head of the caudate nucleus and some of the most inferior fibers of the internal capsule were destroyed (Plate 1).

Thalamic degeneration was severe in n. centralis medialis, n. paracentralis, n. submedius, n. rhomboidialis, and the medial portions of n. medialis dorsalis; moderate in n. reuniens, n. centralis lateralis, the lateral portions of n. medialis dorsalis, and the medial portions of n. ventralis medialis; slight in the more anterior portions of n. ventralis medialis (Plate 1).

Cat CHARLIE: This unilateral lesion was deliberately more extensive than that in ABLE. It extended laterally beyond the anterior rhinal fissure and posteriorly into the pyriform lobe, involving the amygdala. It removed posterior olfactory tubercle and much prepyriform cortex, but did not touch orbito-medial cortex or the caudate nucleus. A few of the most inferior fibers of the internal capsule were interrupted, and a considerable portion of orbital gyrus proreus was ablated (Plate 2).

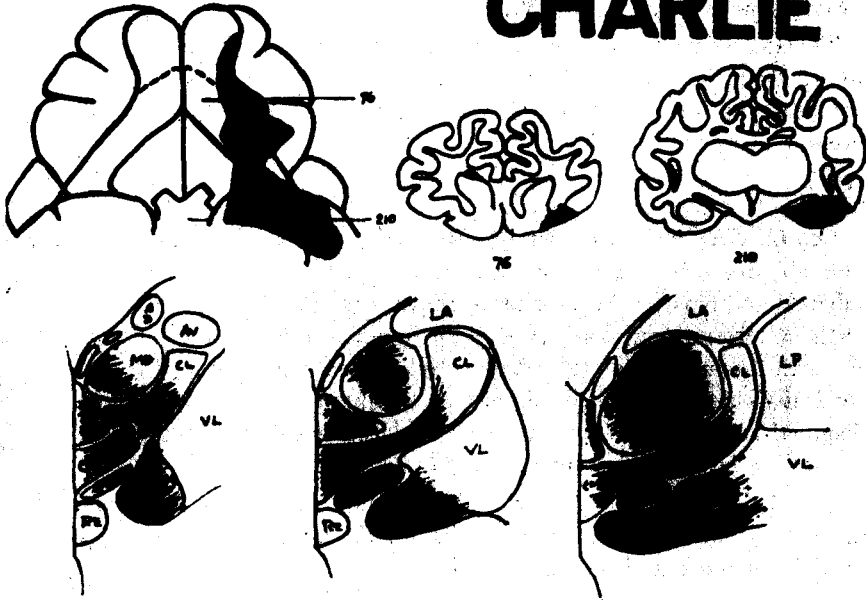
Severe thalamic degeneration was present in n. centralis medialis, n. paracentralis, n. submedius, n. rhomboidialis; moderate in most of n. ventralis medialis and in a few parts of n. medialis dorsalis; slight in n. centralis lateralis and in most of n. medialis dorsalis. No degeneration was present in n. reuniens and some parts of n. medialis dorsalis (Plate 2).

Cat EASY: This was another extensive lesion. It involved the orbital surface of gyrus proreus, anterior olfactory tubercle, prepyriform cortex, anterior portions of pyriform lobe, orbital gyrus, anterior ectosylvian gyrus, anterior sylvian gyrus, antero-limbic and infero-limbic cortex on the left. The lesion also extended across the midline and infringed slightly upon portions of the antero-limbic and infero-limbic cortex on the right. The head of the left caudate nucleus showed moderate atrophy, probably secondary to devascularization, while the inferior left internal capsule was partially ablated (Plate 2).

Thalamic degeneration was severe in n. reuniens, n. rhomboidialis, n. centralis medialis, n. paracentralis, n. submedius, n. ventralis medialis, and n. medialis dorsalis; moderate in n. centralis lateralis; slight in portions of n. centralis lateralis and of n. medialis dorsalis (Plate 2).

Cat FOX: The lesion in this animal was again restricted. It was unilateral, remaining entirely medial to the anterior rhinal fissure and involving anterior olfactory tubercle, prepyriform cortex, and very slight amounts of antero-limbic cortex. Portions of the head of the caudate and the inferior

CHARLIE



EASY



PLATE 2.

fibers of the internal capsule showed gliosis which was probably secondary to devascularization (Plate 3).

Thalamic degeneration was severe in *n. reuniens*, *n. rhomboidialis*, *n. centralis medialis*, *n. paracentralis*, *n. submedius*, and *n. medialis dorsalis*; moderate in some parts of *n. ventralis medialis*. No degeneration was present in *n. centralis lateralis* (Plate 3).

Second Group

Cat GEORGE: This entirely left-sided lesion was quite limited in extent, ablating orbital gyrus proreus, a small portion of the anterior olfactory tubercle and most of anterior prepyriform cortex. It did not extend lateral to the anterior rhinal fissure nor did it impinge upon medial surface cortex. A small amount of white matter subjacent to proreus was the only subcortical tissue involved by this lesion. A limited area in the region of the diagonal band appears to have been replaced by glial tissue, possibly secondary to devascularization (Plate 4).

The thalamic degeneration varied from moderate to slight in portions of *n. centralis medialis*, *n. paracentralis*, *n. rhomboidialis*, *n. submedius*, *n. medialis dorsalis*, and posterior portions of *n. anterioris medialis* (Plate 4).

Cat HARRY: In this, the most limited and superficial lesion of the series, only a very slight amount of posterior orbital gyrus proreus and a somewhat larger area of anterior prepyriform cortex on the left were removed. No other cortical or subcortical structures were involved (Plate 4).

There was minimal degeneration in anterior *n. centralis medialis* and *n. paracentralis* while none was present in any other thalamic nuclei, including *n. medialis dorsalis* (Plate 4).

DISCUSSION

Historical Background

Nissl,²¹ and later Bard and Rioch⁴ and Papez,²² noted midline and intralaminar degeneration with large telencephalic and diencephalic lesions in the cat and dog. Waller²³ found *n. centralis lateralis* and *n. reuniens* cell loss in almost totally hemidecorticated cats. Although the caudate nucleus was damaged in all of Waller's material, no *n. centralis medialis* degeneration was found.

Using retrograde techniques, Rose and Woolsey²⁴ described midline and intralaminar degeneration following forebrain lesions which were more circumscribed than had been previously described. This fact, in view of the similarity between the phylogenetic development of the midline-intralaminar group and that of the allocortex, led them to postulate anterior

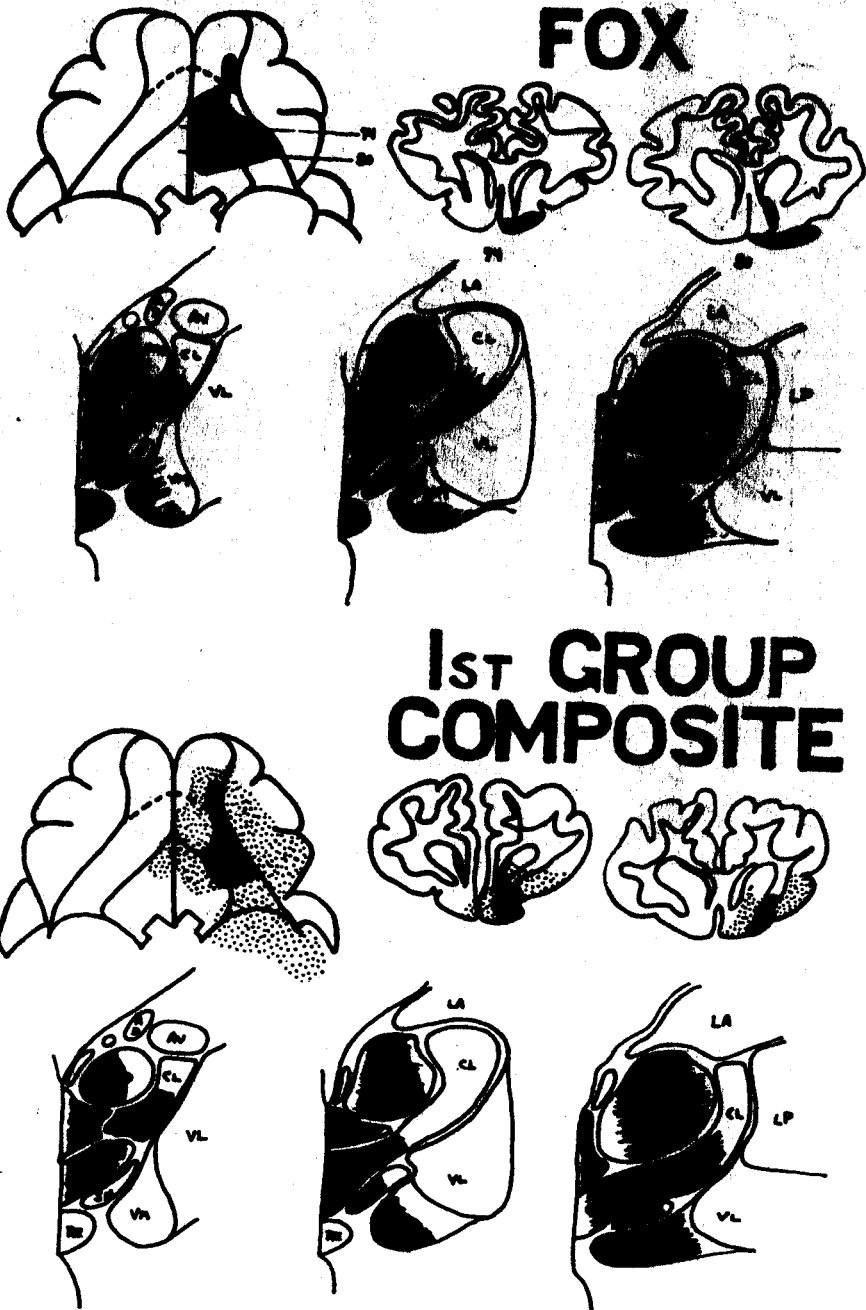
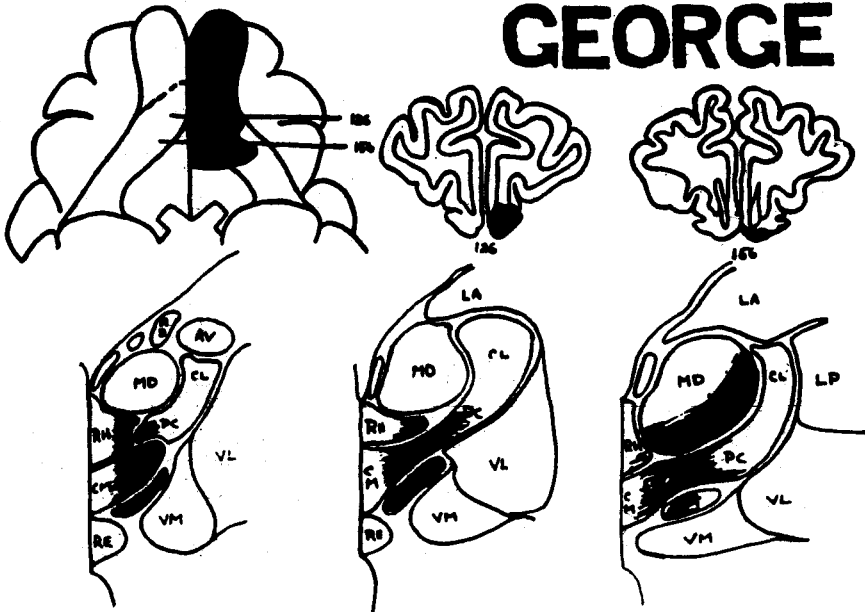


PLATE 3.

GEORGE



HARRY

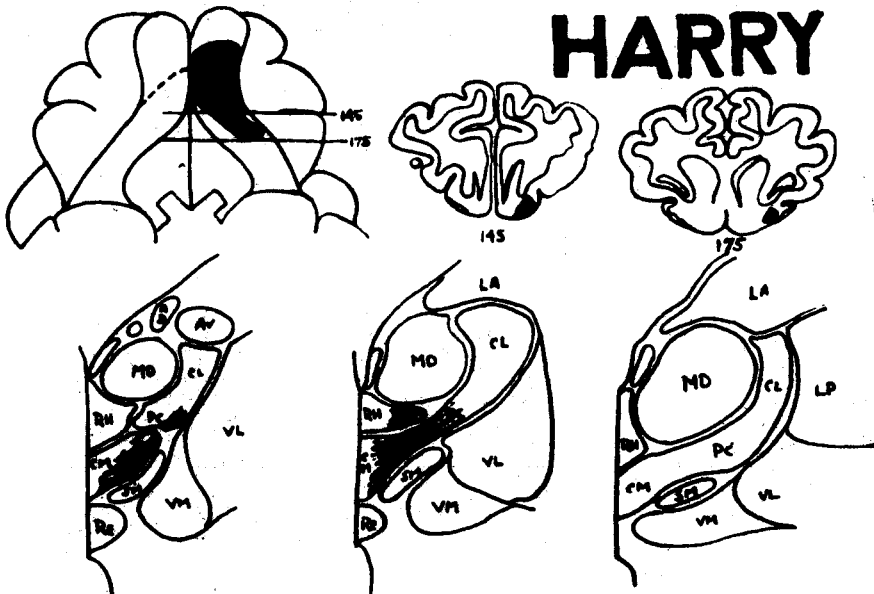


PLATE 4.

rhinencephalic projections from these nuclei. Anatomical analysis of bilateral fronto-temporal ablations in monkeys by Pribram and Bagshaw²² and Bagshaw and Pribram²³ provided further suggestive evidence of such rhinencephalic projections.

Utilizing silver techniques and thalamic lesions, Nauta and Whitlock²⁴ found projections from rostral midline and intralaminar nuclei to "phylogenetically old cortex: prepyriform, infralimbic and limbic cortical area and to presubiculum and entorhinal areas."

Finally, Jasper²⁵ mentions that "there is some evidence that stimulation . . . of mesio-frontal and anterior limbic (cortical) areas may be able to . . . exert generalized effects upon other areas of cortex in both hemispheres."

On the other hand, Walker²⁶ found no evidence of midline and intralaminar degeneration in any of his cortical ablations, and Droogleever-Fortuyn⁷ believes on the basis of his more restricted but still relatively extensive ablations that, with regard to the midline nuclei in the rabbit, "connections with the striate body seem more probable."

Mettler²⁴ described, on the basis of extensive neocortical ablations, "subcortical efferents" of unknown destination from these nuclei.

Powell and Cowan²⁷ state that the midline and intralaminar nuclear group of the rat have an independent projection to the cortex of the medial surface of the hemisphere and to the striatum. Later, Cowan and Powell⁸ found that in a large series of rabbits *n. centralis lateralis* and the more medial intralaminar nuclei degenerated after lesions of the caudate nucleus and denied any cortical projection from these nuclei. A final study²⁸ of the thalamo-striate relationships in the monkey by these same authors seemed to confirm their findings in the rabbit.

Theoretical Formulations

Of the generally accepted thalamic components of the "central activating system," only two, the anterior and reticular nuclear groups, possess projections to neocortex, and of these two, only the reticular complex projects to a sufficiently large portion of the cortical mantle to be able to directly influence generalized cortical activity. However, as Rose²⁹ and Chow³ have demonstrated, this projection is "distributed to the neocortex in a topographically specific manner" with the anterior reticular nucleus degenerating after only more medial cortical ablations. Therefore, since the great bulk of the activating system nuclei, i.e., the anterior and midline-intralaminar groups, do not possess isocortical efferents,^{29,30} they apparently produce the "recruiting response" by means of mechanisms other than a direct, one-neuron corticopetal pathway. On the basis of a somewhat sparse and

often contradictory neuro-anatomical literature concerning this region, there seem to be several alternative, though certainly not mutually exclusive, mechanisms possible.

The midline and intralaminar and anterior nuclei could modify cortical activity via the reticular complex of the thalamus, with neurons originating in the latter forming a sort of "final common path" for impulses from the more caudal portions of the "central activating system."^{8,11}

The midline-intralaminar and anterior nuclei might affect cortical activity on a subcortical level by means of intrathalamic interaction with the medial, ventral, lateral, and pulvinar groups.¹² It is also possible that the "central activating system" nuclei might act on the cortex by means of efferents synapsing in the medial, ventral, lateral, and pulvinar nuclei, with secondary neurons then passing to the specific projection area of each nucleus.

The basal ganglia might similarly function as mediators of impulses from the midline and intralaminar nuclei, although most anatomical studies have thus far failed to reveal significant numbers of striatocortical fibers.⁴ Mettler *et al.* have, however, produced short-latency changes in neocortical electrical activity after caudate stimulation. These authors also describe a "decrease in size" of the caudate and a "loss of cells" in the caudate after cortical ablations.¹³

Finally, the midline and intralaminar nuclei may project to the orbito-frontal allo- and juxtallocortex of the first and second rhinencephalic systems,¹⁴ paralleling the projection of the anterior nucleus to the cingulate juxtallocortex of the third rhinencephalic system.¹⁵ This orbito-frontal cortex would then function as a part of the "central activating system" by elaborating and transmitting midline-intralaminar activity to neocortex via intracortical and cortico-cortical tracts.¹⁶

Of these possible mechanisms, the latter two have seemed most reasonable, in view of the long latency of the recruiting response, 20-35 msec.,¹⁷ and the apparent independence of the response from neocorticothalamic

* The "rhinencephalon" has been defined by Pribram and Kruger as "including all cortical formations not typically isocortical, i.e., those which do not definitely pass through a six layer stage in ontogeny," thus including both allocortical and juxtallocortical formations. Further, on ontogenetic and experimental anatomical grounds, they have grouped these formations into three systems: the first system is semicortical (M. Rose), has direct connections with the olfactory bulb and includes the olfactory tubercle, prepyriform cortex, area of the diagonal band, and the corticomедial nuclei of the amygdala; the second system is perisemicortical and subcortical, has direct connections with the first system, and includes the subcallosal and fronto-temporal juxtallocortex, the septal nuclei and the basolateral nuclei of the amygdala; the third system is archi- and periarchicortical, has direct connections with the second system but none with the first system or bulb, and includes Ammon's formation, the entorhinal, retrosplenial, and cingulate juxtallocortex.¹⁸

reverberating circuits.²⁸ However, opinion has been sharply divided as to whether the basal ganglia or the anterior rhinencephalic cortex receives the principal projection of the midline and intralaminar nuclei.

SUMMARY AND CONCLUSIONS

The lesion common to all animals of the first group, ABLE, CHARLIE, EASY, and FOX, included prepyriform cortex and the orbital surface of gyrus proreus. The only nuclei which degenerated in all four of these brains were: nuclei centralis medialis (CM), rhomboidialis (Rhomb), paracentralis (PC), ventralis medialis (VM), and medialis dorsalis (MD). As reported earlier,²⁸ on this basis it was felt that the evidence was indicative, though not conclusive, that the midline and medial intralaminar nuclei project to anterior rhinencephalic cortex, and that the more lateral intralaminar nuclei project elsewhere.

However, because of the slight subcortical injuries found in all of the first section of animals (Plate 3), additional, more circumscribed, ablations were performed in an attempt to provide material less subject to controversial interpretation. The second group, which comprises cats GEORGE and HARRY, represents this attempt.

These latter two lesions differ only as to the total amount of cortex removed and are similar in that no appreciable subcortical damage is present in either.

In GEORGE, in which a relatively large amount of gyrus proreus and prepyriform cortex is removed, the midline and paracentral degeneration is moderate in degree and quite well-defined in extent. The diffuse pattern of the moderate degree of n. medialis dorsalis cell loss is compatible with the slight interruption of the subcortical fibers to the gyrus proreus. There is no possibility that the internal capsule or the basal ganglia are involved by the lesion (Plates 4, 7).

HARRY presents minimal prepyriform destruction and, quite understandably, the thalamic degeneration is correspondingly minimal. There is definite cell loss in the more anterior portions of the midline and paracentral nuclei, while slight changes are to be noted in n. medialis dorsalis and none in any other thalamic nuclei (Plates 4, 5, 6).

The almost constant severe degeneration in the puzzling n. submedius still remains unexplained, but probably indicates a projection to the cortex within the rhinal fissure.

Therefore, within the limits of the retrograde degeneration technique, the second group of preparations demonstrates, in a more refined and pre-

cise fashion than that of the first, the existence of efferents from the midline and medial intralaminar nuclei to prepyriform cortex.

Needless to say, these findings do not exclude the possibility of other efferents from these nuclei, nor do they indicate possible connections of the more lateral and posterior portions of the intralaminar group of nuclei. Indeed, the more extensive lesions of the first section of brains seem to

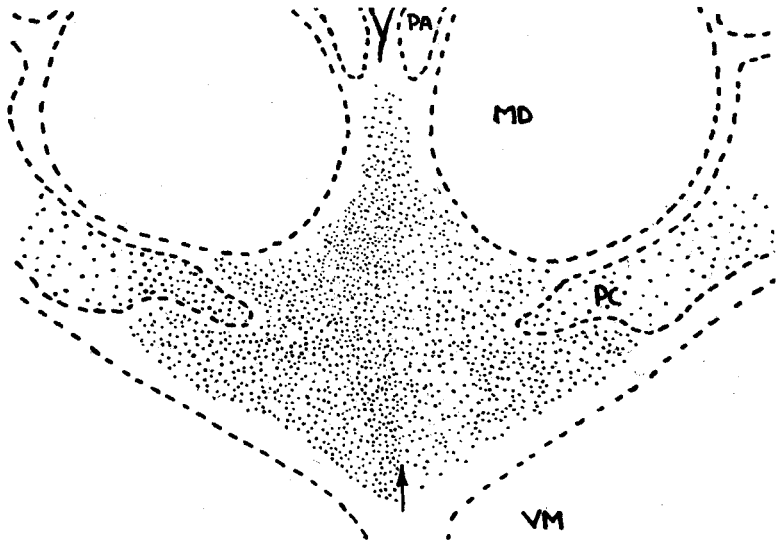


PLATE 5. A drawing of a low-power photomicrograph of Harry (Section #320) $\times 45$. Arrows delineate the midline. Retrograde cell loss on right side of drawing involving CM and medial PC.

indicate that the major projection areas of n. centralis lateralis, lateral n. paracentralis, and n. centrum medianum do not include the prepyriform cortex. This would be quite compatible with the work of Powell and Cowan^{9, 24, 25} in which, after striatum lesions, the more severe degeneration seemed to be more laterally situated than in our material. Further, in our most extensive ablations, there was never degeneration of more than half of the cells in even the more medial nuclei of the midline and intralaminar group, suggesting the possibility of an additional projection elsewhere of the entire nuclear group.

The results of this study suggest, therefore, that all of the thalamic nuclei from which the recruiting response can be elicited project to the rhinencephalon and very closely related striatal structures. The superior midline and medial intralaminar nuclei, n. rhomboidialis, n. centralis medialis, and

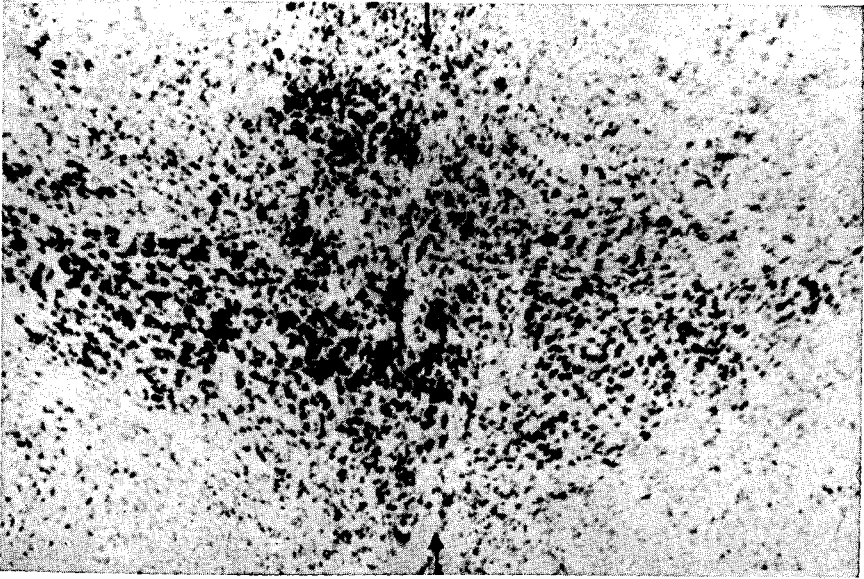


PLATE 6. A photomicrograph of Harry (Section #320) x70. Arrows delineate the midline. Retrograde cell loss and glial proliferation on the right side of the picture, involving CM and medial PC. Thionine blue stain.

14. Mettler, F. A.: Extracortical connections of the primate frontal cerebral cortex. I. Thalamo-cortical connections. *J. comp. Neurol.*, 1947, 86, 95.
15. Mettler, F. A., Hovde, C. A., and Grundfest, H.: Electrophysiologic phenomena evoked by electrical stimulation of caudate nucleus. *Fed. Proc.*, 1952, 11, 107.
16. Morison, R. S., Finley, K. H., and Lathrop, G. N.: Spontaneous electrical activity of the thalamus and other forebrain structures. *J. Neurophysiol.*, 1943, 6, 243.
17. Morison, R. S. and Dempsey, E. W.: Study of the thalamo-cortical relations. *Amer. J. Physiol.*, 1942, 135, 281.
18. Morison, R. S. and Dempsey, E. W.: The production of rhythmically recurrent cortical potentials after localized thalamic stimulation. *Amer. J. Physiol.*, 1942, 135, 293.
19. Morison, R. S. and Dempsey, E. W.: The interaction of certain spontaneous and induced cortical potentials. *Amer. J. Physiol.*, 1942, 135, 301.
20. Nauta, W. J. H. and Whitlock, D. G.: An anatomical analysis of the non-specific thalamic projection system. In: *Brain mechanisms and consciousness*. J. F. Delfresnaye, Ed. Oxford, Blackwell, 1954, p. 81.
21. Nissl, F.: Die Grosshirnanteile des Kaninchens. *Arch. Psychiat. Nervenkr.*, 1913, 52, 867.
22. Papez, J. W.: Thalamic connections in a hemidecorticated dog. *J. comp. Neurol.*, 1938, 69, 103.
23. Penfield, W.: Studies of the cerebral cortex of man. In: *Brain mechanisms and consciousness*. J. F. Delfresnaye, Ed. Oxford, Blackwell, 1954, p. 284.
24. Powell, T. P. S. and Cowan, W. M.: The connections of the midline and intralaminar nuclei of the thalamus of the rat. *J. Anat.*, 1954, 88, 237.
25. Powell, T. P. S. and Cowan, W. M.: A study of thalamostriate relations in the monkey. *Brain*, 1956, 79, 364.
26. Pribram, K. H. and Bagshaw, M. H.: Further analysis of the temporal lobe syndrome utilizing frontotemporal ablations in monkeys. *J. comp. Neurol.*, 1953, 99, 347.
27. Pribram, K. H. and Kruger, L.: Functions of the olfactory brain. *Ann. N. Y. Acad. Sci.*, 1954, 58, 109.
28. Rose, J. E. and Woolsey, C. N.: A study of thalamo-cortical relations in the rabbit. *Johns Hopk. Hosp. Bull.*, 1943, 73, 65.
29. Rose, J. E. and Woolsey, C. N.: Structure and relations of limbic cortex and anterior thalamic nuclei in rabbit and cat. *J. comp. Neurol.*, 1948, 89, 279.
30. Rose, J. E. and Woolsey, C. N.: Organization of the mammalian thalamus and its relationships to the cerebral cortex. *EEG clin. Neurophysiol.*, 1949, 1, 391.
31. Rose, J. E.: The cortical connections of the reticular complex of the thalamus. In: *Patterns of organization in the central nervous system*. Res. Publ. Ass. nerv. ment. Dis., 1950, 30, 188.
32. Starzl, T. E. and Magoun, H. W.: Organization of the diffuse thalamic projection system. *J. Neurophysiol.*, 1951, 14, 133.
33. Starzl, T. E. and Whitlock, D. G.: Diffuse thalamic projection in monkey. *J. Neurophysiol.*, 1952, 15, 449.
34. Walker, A. E.: *The primate thalamus*. Chicago, University of Chicago Press, 1938.
35. Waller, W.: The thalamus of the cat after hemidecortication. *J. Anat.*, 1938, 72, 475.