

Personal copy 45  
0-12

## FURTHER ANALYSIS OF THE TEMPORAL LOBE SYNDROME UTILIZING FRONTO- TEMPORAL ABLATIONS<sup>1</sup>

KARL H. PRIBRAM AND MURIEL BAGSHAW<sup>2</sup>  
*Laboratory of Physiology, Yale University, New Haven, Connecticut*

### SEVEN FIGURES

Klüver and Bucy (Klüver and Bucy, '37, '38, '39; Klüver, '51), confirming and extending the earlier observations of Brown and Schäfer (1888), noted striking changes in behavior following bilateral resection of the primate temporal lobes. These changes can be described as follows:

1. Disturbance of visual processes manifested by altered reactivity to visually presented objects such as food, nails, and snakes; referred to by Klüver and Bucy as "visual agnosia."

2. Changes in dietary habits, as manifested by meat eating.

3. Increased tendency to examine objects visually, tactually, and orally; referred to by Klüver and Bucy as "hypermetamorphosis." Classified separately by them, the oral component was termed as "oral tendency."

4. Changes in behavior toward other organisms. These were described as "increased tameness," loss of "fear," and "hypersexuality."

Klüver and Bucy ('39) attempted to fractionate this syndrome by making subtotal removals of temporal cortex. Because it is difficult to reach the medial portions of the lobes without damage to lateral structures, they restricted these

<sup>1</sup>Supported in part by a grant from Contract VAm 23379 of the Veterans' Administration.

<sup>2</sup>The authors are indebted to Dr. John Fulton for making this study possible and for his interest and encouragement throughout its prosecution.

subtotal ablations to the lateral temporal cortex. These operations failed to alter general behavior. More recently, in both carnivores and primates, Bard and Mountcastle ('48), and Thomson and Walker ('50) have observed some of the characteristic effects of temporal lobectomy on general behavior when the lesions were restricted to the polar and medial portions of the temporal lobes, directing attention to the region of the amygdaloid complex as a possible cerebral focus for such functions. However, it is not clear from these studies just which basic functions have been disturbed by the various lesions; it is not apparent, for example, when an animal indiscriminately puts meat, snakes, or bolts into its mouth following bitemporal lesion, whether this is due to interference with taste, olfactory, visual and/or tactual processes; whether the animal is generally deteriorated or "stupid"; or, whether there has resulted a change in appetitive mechanisms related to metabolism. In the present study, in addition to systematic observations of general behavior toward inanimate and animate objects, visual functions, taste preference, ability to solve complex problems, as well as some of the factors related to energy balance (food intake, level of general activity, and basal body temperature) were tested quantitatively. (Quantitative olfactory tests were attempted but failed to provide reliable information.) The pattern of postoperative performance on this constellation of observations and tests provided some data relevant to the problem of fractionating the temporal lobe syndrome.

Concomitantly, a more precise definition of the anatomical substrate implicated in this behavior syndrome was attempted. The failure of previous selective ablation studies to fractionate the temporal lobe syndrome led to a search for a more satisfactory basis for making ablations. In primates, the division of the cerebral hemispheres into lobes on a gross anatomical basis is emphasized by cranial and cerebral configuration. Often investigations have been too much under the influence of such gross distinctions in spite of the fact that other methods (e.g., microanatomical, electrophysiologi-

cal) suggest subdivisions which cut across these gross anatomical boundaries. In the present experiments, data obtained by the method of strychnine neuronography were chosen as a basis for making ablations. In this way, the relevance of these data to behavioral problems is tested. Will this method of cortical parcellation lead to the fractionation of the behavioral syndrome?

Neuronographic studies (Bailey, von Bonin, Garol and McCulloch, '43; McCulloch, '44; Petr, Holden and Jirout, '49; Pribram, Lennox and Dunsmore, '50; Pribram and MacLean, '53; Sugar, French and Chusid, '48) had suggested that portions of the temporal cortex are functionally related to areas outside the confines of the gross anatomical subdivision called temporal lobe. Neuronographically defined cortical subdivisions "frontotemporal," "medial occipitotemporal," and "lateral temporal" are discerned. The "frontotemporal" region includes the posterior orbital, anterior insular, temporal polar and periamygdaloid (pyriform) cortex. The "medial occipitotemporal" region includes the cortex of the hippocampal and fusiform gyri. The "lateral temporal" subdivision includes the cortex of the supratemporal plane and superior temporal gyrus. In addition, on the basis of neuronographic data the frontotemporal region is closely related to the amygdaloid complex; both the frontotemporal and medial occipitotemporal regions are related to the hippocampus.<sup>3</sup>

Studies implicating the integrity of the medial occipitotemporal region in visual discrimination behavior have been reported elsewhere (Ades and Raab, '49; Blum, Chow and Pribram, '50; Chow, '51; Mishkin, in press; Mishkin and Pribram, in press; Riopelle, Harlow, Settlage and Ades, '51). These studies support the suggestion of Klüver and Bucy

<sup>3</sup> Neuronographic data suggest that three parts of Ammon's formation are efferently connected with three cortical regions: the frontotemporal, medial occipitotemporal, and medial parieto-occipital. No efferent intracortical pathways have been established, however. Thus, the existence of the hippocampus as a separate "region" is at present undetermined (Pribram, Lennox and Dunsmore, '50; Pribram and MacLean, '53).

(1939) that the "visual agnosia" observed in their animals is due in part at least to involvement of cortex referred to in man as "visual association" cortex. They also emphasize that this tissue extends further forward into the inferior part of the temporal lobe than had been previously thought.

Much less is known of the other aspects of the temporal syndrome and their relation to the other neurographically determined cortical subdivisions. As already stated, some of the grosser changes in general behavior have followed lesions restricted to the polar and medial portions of the temporal lobe. Since these alterations resemble some of those attributed to lesions of the frontal and cingulate areas, viz., "loss of fear," altered "social awareness" (Bianchi, '22; Glees, Cole, Whitty and Cairns, '50; Smith, '45; Ward, '48), it seemed reasonable that interference with the frontotemporal region as determined neurographically might clarify aspects of the temporal lobe syndrome not related to vision. Specifically, it was postulated that frontotemporal resections would drastically interfere with some but not all aspects of behavior examined by the observations and tests utilized. From such selective interference it could then be inferred that the frontotemporal cortex is implicated in a group of functions which could be clearly differentiated from the rest of the temporal lobe syndrome.

#### MATERIALS, METHODS AND PROCEDURES

*Subjects.* Ten subjects, one adult male *Chaema* baboon, one adult female Guinea baboon, and 8 immature rhesus macaques were used. The adult male baboon and 5 immature macaques received lesions invading the whole extent of the frontotemporal region. Two additional immature macaques and the mature female baboon had ablations restricted to either the orbital, insular, or temporal areas. The other macaque, used as a control, was subjected to surgery of the anterior cingulate gyrus. The baboon and 4 of the macaques receiving the more extensive lesion were tested both pre- and postoperatively on the complete battery of behavioral tests described below. They

were also systematically observed for gross changes in behavior, especially with regard to reactions to noxious and social stimuli. The other macaque with the extensive lesion and his control, the animal with the anterior cingulate ablation, were investigated for quantitative estimation of factors related to energy homeostasis. The animals with the more restricted ablations were tested only with respect to those behavioral aspects which, on an *a priori* basis, were thought most likely to be associated with the particular cerebral area investigated.

### *Tests*

#### *A. Visual processes*

1. Visual fields. The extent of the visual fields is tested by two methods. An object is brought into the subject's visual field from the periphery, and the point at which the animal begins to follow the object is noted. The second method consisted of a simultaneous presentation to the animal of a linear arrangement of peanuts. A record is kept of the order in which the animal chooses the peanuts. Deficits in the visual field become apparent when the animal consistently ignores the peanuts in a certain portion of the field, or when this portion is consistently ignored until the animal shifts position after having removed all the other peanuts presented.

2. Visual pursuit. A piece of food is presented to the animal at the end of a stick while another piece of food is held just beyond reach near the center of the animal's visual field. The stick is systematically moved in space and the animal's eye, head, body, and hand movements are observed.

3. Visual acuity. A peanut is attached to the end of a black thread placed on a black background. The peanut is placed beyond the animal's reach; the thread within its reach. Various diameters of thread are used, to a minimum diameter of 4-0 USP surgical thread. The thread of the smallest diameter which the animal manipulates in order to obtain the peanut is recorded.

4. Visual-pattern discrimination. Patterns are painted in black against a yellow background. A plus (+) and a square of approximately equal area are simultaneously presented to the animal as covers of food wells. Correct choice is rewarded when the animal uncovers the food well and receives a peanut. The animals are trained until performance level passes an arbitrary criterion of 90% correct on 100 consecutive trials.

5. Observations of visual behavior. The animals are observed with respect to attentiveness to large and small objects; to moving and stationary objects; to objects brought into the field of vision while they are actively attending to other objects. Presentations are made so as to elicit visual or tactile response.

6. Discrimination of food from nonfood objects. A board with 20 objects, each approximately the size of a peanut, is presented to the animal. Of these objects three are familiar food morsels (banana, cracker, peanut, orange, etc.). The others range in color, brightness, form, and texture from wood and cork to steel nuts and bolts. The order of choice of objects was recorded. (This is not strictly a visual test. Manipulation may help in the identifying process.)

### *B. Taste*

Pieces of bread and potato are soaked in concentrated quinine solution and acceptance or rejection recorded. Determinations are made of acceptance thresholds for quinine solution by the quantitative taste preference method (devised by Patton and Ruch, '44). Acceptance of food other than vegetable was examined in several instances.

### *C. Approach and avoidance*

1. To inanimate objects. This behavior is tested as part of the previously described "food-nonfood" discrimination test, and also by repeatedly presenting to the animal a variety of non-edible and often noxious objects: sharp pieces of metal, lighted matches, and burning paper. A stimulus object is considered noxious if it visibly injured the animal's integument by cutting or burning. The number of times in a session that an animal would approach, accept, and examine such an object is recorded.

2. To other organisms. A record is made of the approach and avoidance to other operated and normal animals of the same size and species. Also, the animal's reactions to a "friendly" and a "hostile" observer are recorded.

### *D. Delayed response*

A peanut is placed in one of two apparently identically covered food wells in full view of the animal. An opaque screen is then lowered between animal and food cups for as long as 15 seconds. The screen is raised and the animal allowed to choose between food wells. Correct choice only is rewarded with a peanut found in "correct" cup. The animal is trained to a preoperative criterion: 85% correct on 100

consecutive trials. Postoperatively, the animal's ability to reach same level of performance is tested.<sup>4</sup>

#### *E. Factors related to energy metabolism*

The animals are kept in an air conditioned (80°F.) soundproofed environment throughout the experiment. The daily intake of an ad libitum amount of prepared lab chow is recorded. General activity is measured in an activity cage.<sup>5</sup> Daily rectal temperature records are kept. Sleep-activity cycles are observed.<sup>6</sup>

*Surgical procedures.* All operations were performed in two stages one to two weeks apart, each stage being limited to one hemisphere. Under intraperitoneal sodium amytal anesthesia (approx. .6 cm<sup>3</sup> per kilogram of 0.1% soln.), a linear incision was made in the temporal region. Temporal muscle was split, the zygoma resected for its full length, and a burr hole made in the temporal bone. This burr hole was enlarged by rongeur to expose the entire temporal polar area, and extended upward and forward to expose the inferior frontal area. The dura was opened in a cruciate fashion. The head of the animal was then placed in such a position that by gentle retraction the orbital gyri of the frontal lobe and the periamygdaloid and uncal areas of the temporal lobe were visualized. The posterior orbital gyrus, the temporal polar and periamygdaloid cortex were then subpially resected. The pos-

<sup>4</sup>The authors wish to thank Dr. Joseph Epstein and Mr. Milton Brightman for their help in testing and observing animals in this part of the experiment.

<sup>5</sup>The authors wish to thank Dr. George D. Davis for the use of this apparatus, a detailed description of which is to be found in Davis ('51), and Mr. Robert Zeppa and Mr. Al Cuppola for their help in carrying out the other metabolic tests. Thanks are also due Dr. John Brobeck and Dr. James A. F. Stevenson for their advice and supervision of this part of the experiment.

<sup>6</sup>The techniques, although quantitatively recorded, do not entirely overcome difficulties encountered in devising foolproof tests. Food spillage is a case in point. Although we believe that all spilled food was recovered and weighed we cannot be certain of this. In the same manner, although every precaution was taken to accustom the animals to the rectal temperature-taking procedure, it cannot be said with certainty that the relaxation of the animal was the same pre- and post-operatively. The use of a control animal countered these difficulties in part. The data are, therefore, presented with the hope that they will induce others to pursue this difficult but important phase of the investigation.

terior and superior limits of the temporal resection were marked by the temporal horn of the ventricle, and by visualization of the optic radiations. Medially, the limits of the resection were more difficult to determine, and were established only by judgment based on experience. In all instances the resection of the anterior portion of the cortex of the Island of Reil was left to the end. This cortex was approached through the Sylvian fissure which was opened by gentle retraction with two brain spatulae. Only occasionally was there inadvertent damage to the frontal operculum or supratemporal plane following this procedure. The insular cortex was subpially resected in such a manner that the margins of the lesion extended to those of the posterior orbital and temporal resections. Posteriorly an attempt was made to extend the lesion to an imaginary line connecting the base of the central fissure with the vein of Labbé. Often an anastomotic branch of the vein marked this line. Two difficulties had to be overcome with respect to the ablations of anterior insular cortex. Unless great care was taken to handle the middle cerebral artery gently, and for only short periods, the artery would contract and occasionally thrombose. Because of the presence of the claustrum it was often difficult to determine whether the extreme or external capsule had been reached. Both these difficulties were overcome by designing a small-bored, flexible suction tip with thumb control. An 18 or 19 gauge needle stock was found most suitable for this insular resection; for the remainder of the resection an 18 or 17 gauge was found more desirable. Bleeding was minimal at all times and was controlled by packing. Electrocautery was not used on cortical surfaces. Each wound was thoroughly irrigated with warm saline solution before tight closure of the dura. Interrupted silk technique was used throughout the muscle and galeal closure. Subcuticular continuous suture was used in the scalp. No dressing was found necessary. Antibiotics were not used postoperatively and there was no incidence of scalp infection. As a rule, the animals were up and about 2 to 4 hours after closure, following the first stage. Following the second stage,



the animals would often stir and move in about the same length of time, but would rarely be up until 12 to 18 hours after operation. No late postoperative complications occurred in the animals reported. Three additional animals were not included in this report; one macaque had extensive invasion of the internal capsule on one side at the time of operation; two animals (one adult male baboon and one immature macaque) suffered hemiplegia secondary to middle cerebral artery thrombosis. In the case of the macaque this progressed over a period of one month and became terminal.<sup>7</sup>

*Histological verification of lesions.* All subjects were sacrificed approximately 4-8 months after operation. The brains were perfused with saline and 10% formalin, fixed in 10% formalin, dehydrated with increasing concentrations of ethyl alcohol and serially sectioned at 25  $\mu$  thickness. Every 10th section was saved; every 20th section was stained with aniline thionin. Every 4th stained section (2 mm apart) was used to reconstruct the lesion. Analysis of resulting retrograde thalamic degeneration is also reported.

#### OBSERVATIONS OF BEHAVIOR

A protocol typical of the baboon and the 4 macaques receiving the extensive frontotemporal lesion follows:

*Preoperatively.* The animal was active, friendly and responsive to feeding and petting. Preoperative formal training included visual tests, taste preference, and the delayed response test. Although inedible objects on the food discrimination board were approached during the early trials, the animal quickly learned to ignore them. By the second day of testing, no interest was shown in inedible objects. After two experiences with noxious stimuli (sharp instrument and lighted match) the animal retreated to the far end of the cage, and would not return to the front of the cage during the test session. On subsequent examination with a lighted match he cautiously approached and touched once again, but thereafter

<sup>7</sup>The authors gratefully acknowledge the help of Mr. L. Kirby and Mr. Al Cuppola for their surgical assistance.

covered in the back of the cage making swiping motions with his hand to his nose. Interoperative testing following the first stage frontotemporal removal revealed no change in his general behavior, or in the performance on formal tests.

*Postoperatively.* After the second operation a profound change was noted. Without prior planning, the authors independently felt it safe to enter the animal's cage and "petted him for a considerable time." When the observer placed his hand in the animal's mouth it was chewed very gently. Equally dramatic was the "hypermetamorphotic" behavior. It was difficult to dis-attach the subject from wristwatch, ring, or tie. Intense and prolonged examination of the smallest grains of sawdust, dirt, and marks on the cage occupied hours of the animal's time. Alternating with these periods of "hypermetamorphosis" were periods of drowsiness and sleep. These were characterized by a rather sudden onset, sometimes in the middle of a testing session. During such a drowsy period, the animal could be roused with difficulty; once roused his "hypermetamorphotic" behavior again became evident. Every movable object found its way into the animal's food pouch; even sharp objects were orally manipulated. Chewing was often so vigorous that bleeding of the gums resulted. Lighted matches and paper were repeatedly approached, grabbed, and put into the subject's mouth. Occasionally the animal's whiskers would catch fire. He would douse his snout in the water trough when this occurred. Burned paws were cooled in water. In spite of the obvious discomfort these noxious agents seemed to cause, the animal would return over and over again to expose himself to injury. When attacked by a larger animal he would not attempt to escape, but would sit quietly ducking the debris thrown at him, wincing or grimacing briefly when hit or bitten. Should the subject be cornered, however, he might show aggressive behavior briefly, i.e., until he extricated himself from the immediate situation, then he would sit calmly watching the excitement usually manifested by the remainder of the primates in the room. When placed with control animals over whom he had been dominant in a food

situation prior to operation, he was no longer dominant in spite of apparently increased "oral tendencies." During this same period the subject showed normal acuity on the "string pull-in" test, had normal visual fields, and performed at criterion level on the visual-discrimination and the delayed-response tests. On the "food-nonfood" discrimination, however, inedible objects were placed in the mouth as often as food objects, without order of preference.

No sudden change in behavior characterized the ensuing months. Gradually, however, the tolerance to noxious stimulation decreased. After three months there was some hesitation, and attempts to discriminate between food and inedible objects, especially injurious ones, appeared. Nevertheless, he would still accept lighted pieces of paper and matches except immediately after feeding. In another month, however, this happened only when the animals had been fasted for over 24 hours. At no time did control animals show this persistence of approach to objects which visibly injured them. The animal gradually began testing inedible objects by biting and manipulation, discarding these objects rather than storing them in the food pouch. During this entire period, the subject would accept pieces of cotton, potatoes and bread soaked in quinine solution, chew on them with gusto and spit out inedible things such as cotton only after a considerable time. Control animals, as a rule, did not repeatedly accept such objects soaked in quinine. A few would take potato repeatedly but grimace when they chewed it. None took the cotton after a few trials. There was some temporary lowering of threshold in the quantitative quinine preference test. No change in other formal tests (given for one week each month) occurred, once criterion had been reached. The animal was sacrificed in the 6th postoperative month. Significant deviations from this typical protocol are recorded for each animal in table 1 and in the following descriptions:

*FT1.* This large adult male baboon was not tested in the quantitative taste preference test because he was too large

	EE		EE		EE		EE		EE	
Approach to other organisms	No change.		More approach behavior.		Not examined.		Much more approach behavior.		Much more approach behavior.	
Avoidance of noxious stimuli	Repeated contact.		Repeated contact.		Temporary change only.		Repeated contact.		Repeated contact.	
"Hypermetamorphosis"	++++		++		+ Temporary		++++		++++	
Food-nonfood discrimination	Indiscriminately took all objects for 3 mo. Then, food taken first, non-food objects when food was gone.		Food first; then nonfood objects.		Did not pick up nonfood objects. Ate feces.		Food first; then nonfood objects.		Indiscriminately took all objects. Ate feces.	
Taste preference	Ate meat; accepted bitter objects.		Did not eat meat (fig. 1 A).		Did not eat meat (fig. 1 B).		Did not eat meat (fig. 1 C).		Ate meat (fig. 1 D).	
Visual fields	No change.		Left homonymous hemianopia for 3 weeks postop.		No change.		No change.		No change.	
Visual pursuit	No change.		No change after recovery from hemianopia.		No change.		No change.		No change.	
Visual acuity	No change.		No change.		No change.		No change.		No change.	
Visual pattern discrimination	Pre	Post	Pre	Post	Pre	Post	Pre	Post	Pre	Post
	580	50	50	0	205	0	380	200	250	100
Delayed response	Not examined.		Pre	Post	Pre	Post	Pre	Post	Pre	Post
			200	100	300	0	750	300	1250	400

Tabulation of some of the changes following bilateral frontotemporal resections. +++ indicates repeated immediate approach to small objects. ++ indicates repeated approach to such objects during separate sessions but selectivity developing during a particular session of trials. + indicates approach to first presentation, each session with subsequent selectivity. In tabulating results of visual discrimination and delayed response performance number of trials required to reach criterion of 85% correct responses on 100 consecutive trials preoperatively (pre) is compared with number of trials taken to reach this criterion postoperatively (post). As indicated by the interoperative performance of these animals perfect retention can be obtained following intracranial surgery. However, in this and other studies, a deficit in relearning or performance was not assumed to be present unless more trials were necessary for reacquisition than had been taken in initial learning.

for the equipment. He was sacrificed 5 months postoperatively because of bronchopneumonia.

*FT3.* This immature female macaque was preoperatively the least dominant animal tested; therefore, no data on aggressive behavior were obtainable. After the second operation a left homonymous hemianopia appeared and persisted for three weeks. This subject never placed inedible objects into its food pouches but always tested them by biting; thereupon discarding inedible objects. She chose food objects before inedible objects in the "food-nonfood" discrimination situation, but would then proceed to examine orally the inedible objects. (See fig. 1 A for preference thresholds for quinine.)

*FT4.* Immature male macaque. This animal received daily intramuscular injections of streptomycin because of a positive tuberculin test recorded in the interoperative period. No postoperative evaluation of social behavior could be made. General behavioral changes were marked immediately after the second operation, but improved more rapidly than those of the other animals. He did not, however, return to his preoperative aggressive behavior. Lighted matches, sharp and inedible objects were not approached. The animal was sacrificed for histological study after the 6th postoperative month. (See fig. 1 B for preference thresholds for quinine.)

*FT5.* Immature male macaque. This animal attempted to mount any large object such as a broom handle, a sharp piece of metal or another macaque. Food objects were chosen first, whereupon inedible objects were examined orally. Any soft inedible objects such as feces were ingested. The dominance picture following operation was complex. The animal repeatedly approached food, inedible, and animate objects for eating, grooming, or mounting behavior for prolonged periods; if another animal turned aggressively toward the subject he would retreat momentarily, and remain away as long as the aggressive attitude was maintained on the part of the other animal. Almost immediately after cessation of the aggressive posture, however, the subject would resume an attempt at approach, only to be rebuffed again. This behavior might

persist for hours until one animal was removed or until the unoperated monkey would tolerate approach. (See fig. 1 C for preference thresholds for quinine.)

*FT6.* This immature male macaque showed increased post-operative manipulation of genitals and mounting behavior

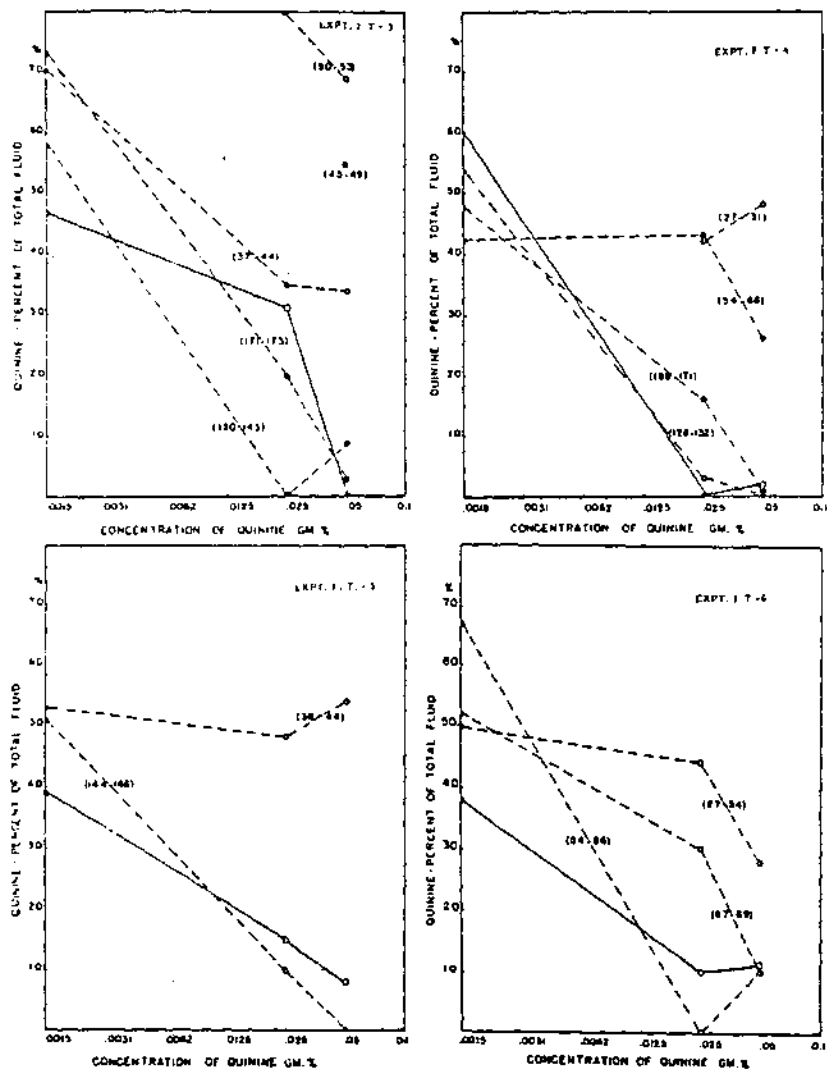


Fig. 1. Graphs of quinine acceptance thresholds pre- and postoperatively for animals which received frontotemporal lesions.

similar to that of FT5. (See fig. 1 D for preference thresholds for quinine.)

*FT2.* This immature male macaque was examined with respect to factors related to energy homeostasis. He was studied together with a control animal (which received a bilateral anterior cingulate ablation) in an air conditioned, sound-

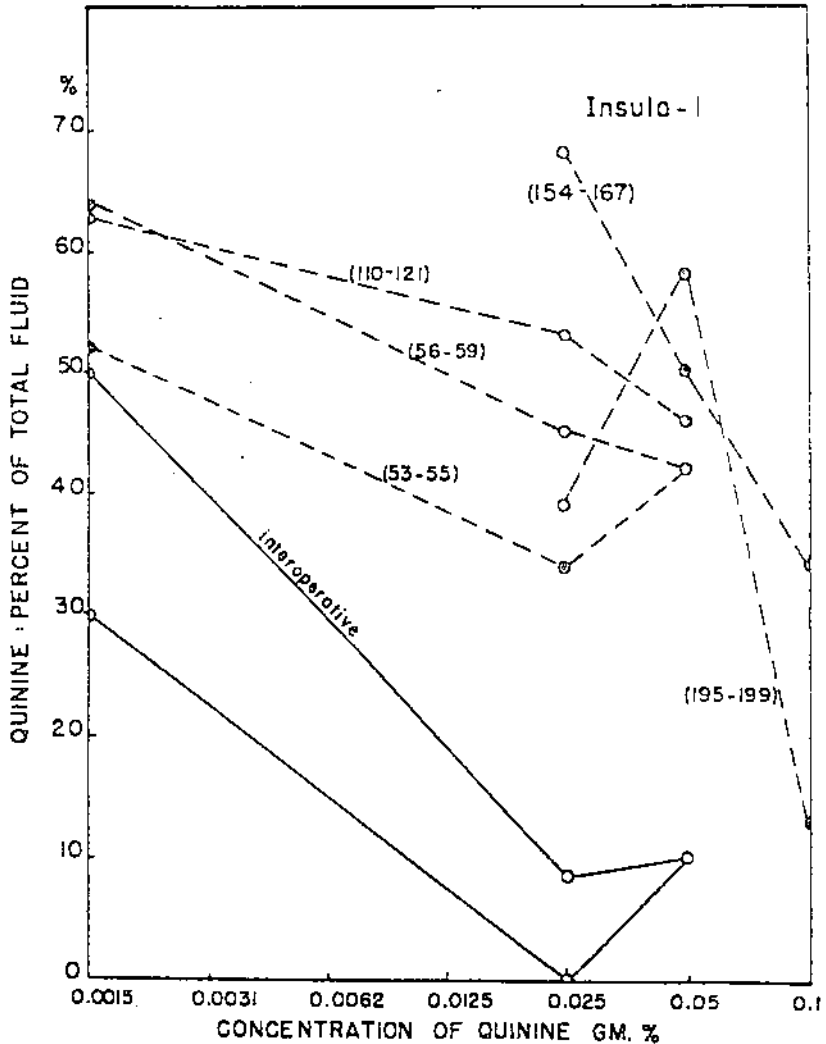


Fig. 2 Graph of pre- and postoperative quinine acceptance thresholds for animal which received extensive ablation in region of anterior insula.

proofed environment. Food intake, rectal temperature, and activity were measured. After the first frontotemporal ablation, activity (as measured on three separate occasions in an activity cage for three hours) was markedly increased over the preoperative level (fig. 3). After the second operation,

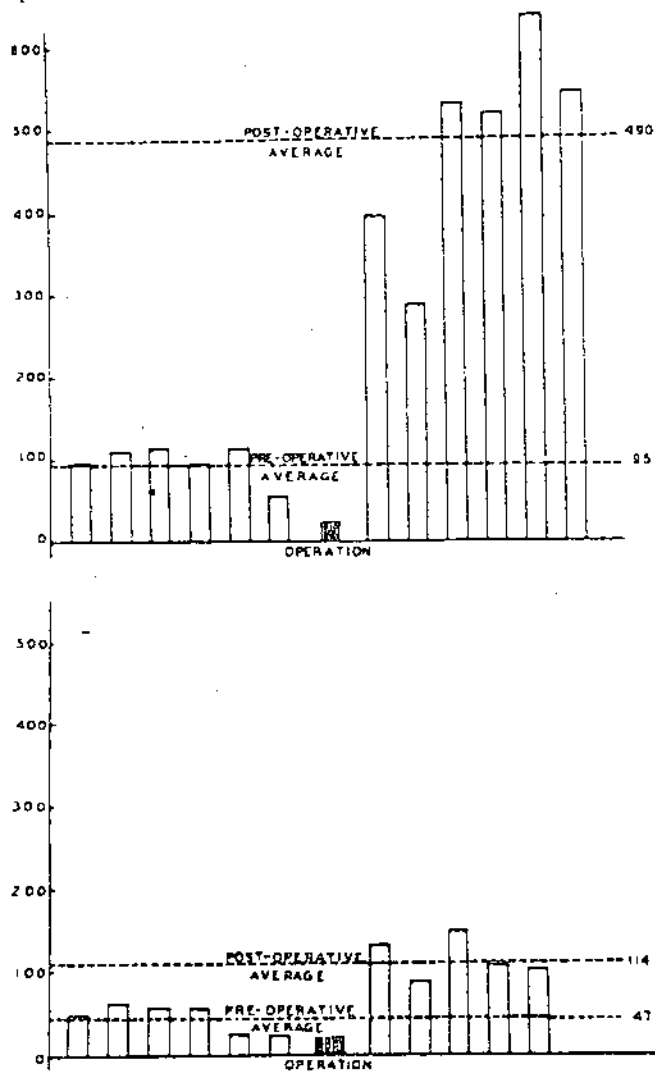
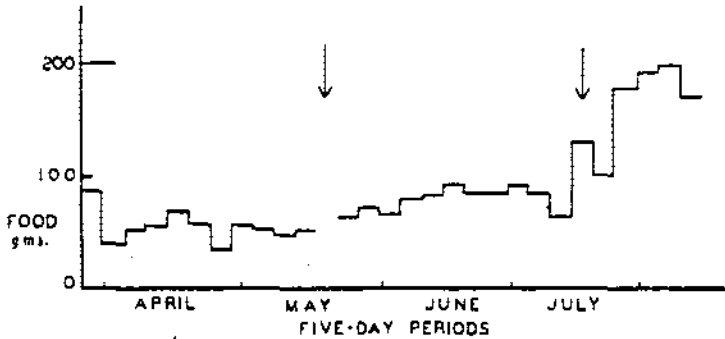


Fig. 3. Graphs of activity records of subjects FTE and the control with the anterior cingulate gyrus ablation. Each bar represents a three-hour period of testing in an activity cage. Ordinate represents number of movements made toward sides



the increased activity persisted and the animal doubled its daily food intake (fig. 4). A degree drop in the mean rectal temperature was recorded (fig. 5). No such marked changes followed the cingulate operations on the control animal. The changes noted for subject FT2 persisted until death one Sunday morning when the air conditioning apparatus was found out-of-order and the temperature of the room had risen to 102°F. The control animal seemed unaffected by this temperature change but FT2 appeared limp with shallow, irregular respirations. The rectal temperature reflected that of the



FT-2

Fig. 4 Graph of pre- and postoperative food intake for subject FT2. The control animal with anterior cingulate gyrus ablation showed an increase over preoperative food intake only for first 5 postoperative days.

room. After the room was cooled the animal's rectal temperature came down, but his general condition continued critical. It was therefore sacrificed in preference to risking death and deterioration of its central nervous system before discovery.

*F1.* Subtotal ablations were made in three animals in consideration of factors of mass and localization. The effects of posterior orbital gyrus removals on the activity of macaques has been reported elsewhere (Davis, '51). Histological analysis of the brains of these animals is lacking with the result that the anatomical problems connected with that study remained unanswered. Doctors Davis, Livingston and Fulton kindly made available the data and brain of one of these

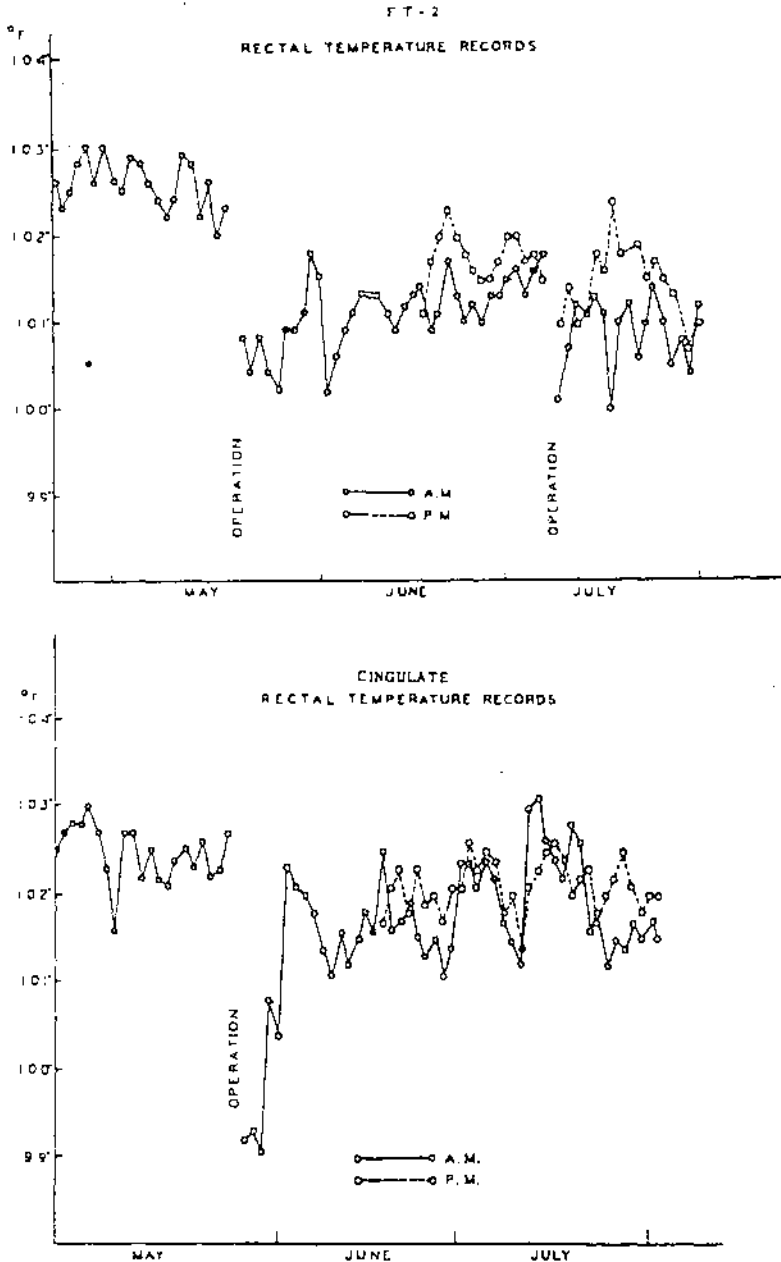


Fig. 5. Graphs of daily rectal temperature of subject FT-2 and its control which received an ablation of the anterior cingulate gyrus. All recordings of food intake, activity, and rectal temperature were obtained in an air conditioned room with temperature kept at  $80^{\circ}\text{F.} \pm 3^{\circ}\text{F.}$

animals for inclusion in the present study. Except for the changes in activity, similar to those shown in figure 3 A, no alterations in general behavior were observed. No taste tests were performed.

*I1.* One immature macaque was subjected to restricted bilateral anterior insular removal and acceptance threshold for quinine measured. A marked impairment on this test followed operation and persisted for the 7 months prior to sacrifice (fig. 2). In spite of this, the animal would not accept meat. No gross changes in general behavior were noted.

*T2.* None of the animals with restricted orbital or insular lesions had shown gross changes in general behavior. In order to confirm the reports of others that medial and polar temporal lesions were responsible for this change, an animal with bilateral polar temporal and amygdaloid removal was prepared and observed. This adult female Guinea baboon showed no interoperative changes. Immediately following the second operation the gross alteration in general behavior described for the more extensive lesions occurred. She would not accept cotton soaked in a saturated solution of quinine, and refused meat. She was sacrificed 6 months after the second operation.

#### ANATOMICAL OBSERVATIONS

In general, the lesions were bilaterally symmetrical and included most of the cortex of the posterior orbital gyrus, anterior and limen insulae, and the temporal pole. In addition, the periamygdaloid cortex and amygdala were extensively involved (figs. 6 and 7). In subjects FT1, FT3, FT5, F1 there was unilateral or bilateral invasion of the head of the caudate nucleus; in subjects FT3, I1 the putamen was involved in the lesion; in subjects FT3, FT4 a small portion of the posterior amygdaloid nuclei was spared; and in subjects FT4, FT5 the anterior insular cortex was slightly damaged. Retrograde degeneration occurred in the n. medialis dorsalis pars parvicellularis in animals FT2, FT3, FT6, F1; in pars magnocellularis in all animals with the extensive frontotemporal lesion

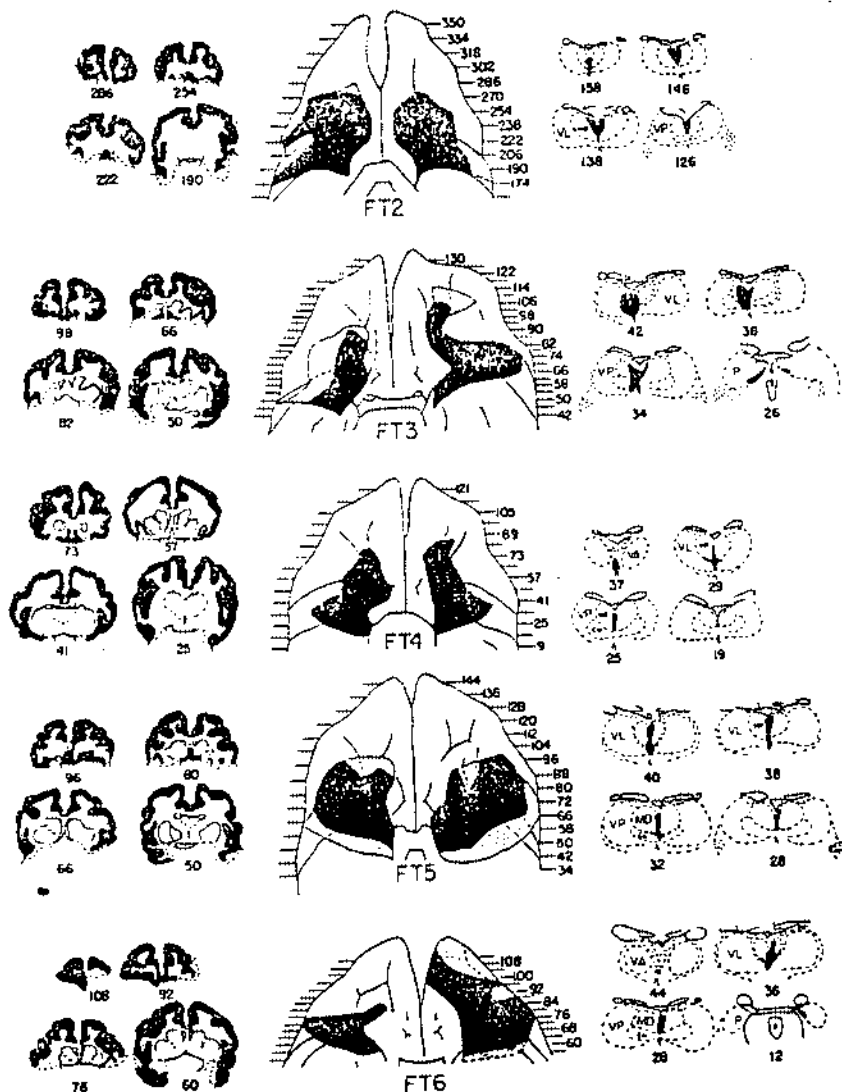


Fig. 6 Ventral reconstructions of lesions of subjects FT2, FT3, FT4, FT5, FT6 (partial cortical lesions are represented by stippled areas; total cortical lesions by black areas). Representative cross sections of cortex (represented in black) indicate depth of lesion. Numbers represent serial order of section. Cross sections of thalamus show areas of degeneration in black. MD, n. medialis dorsalis; CM, n. centromedian; VA, n. ventralis anterior; VL, n. ventralis lateralis; VP, n. ventralis posterior; P, n. pulvinaris.

and in subject F1; in the n. medialis ventralis (reuniens) in all animals with the extensive frontotemporal lesions and in subject TP; in the other midline and medial intralaminar nuclei in all animals with the extensive frontotemporal lesions and in subject F1; and in the medial pulvinar in animals FT3, FT6, TP, II.

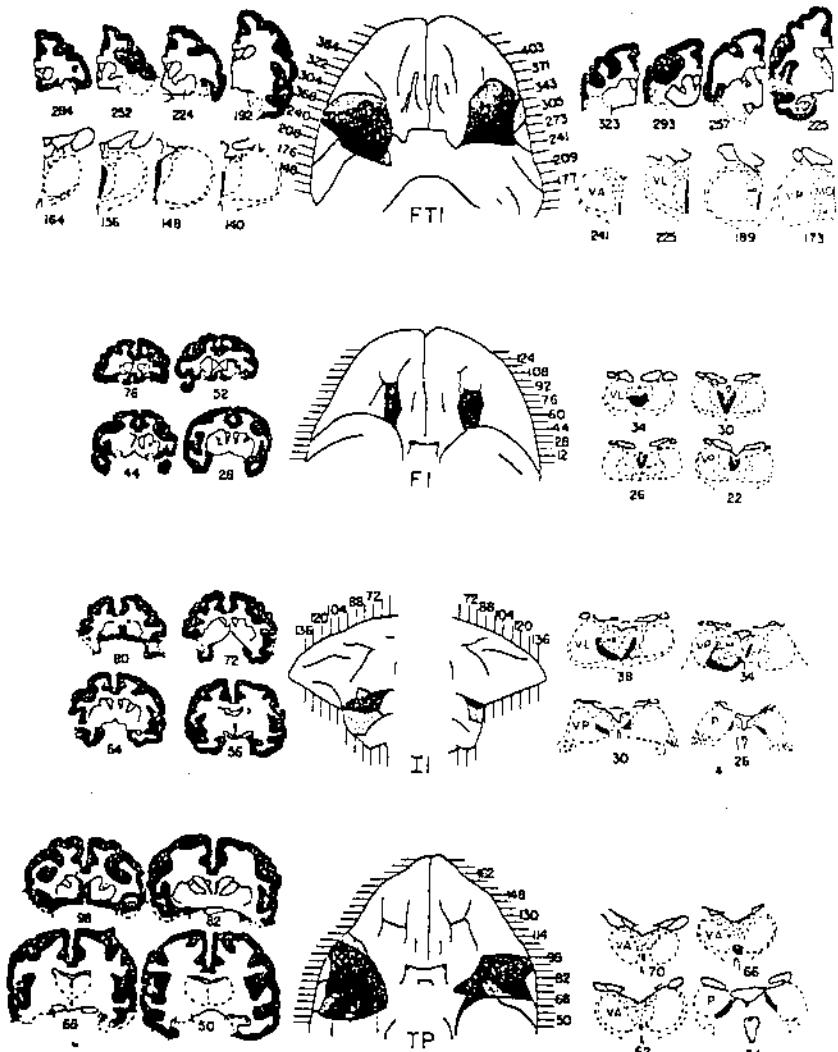


Fig. 7. Ventral reconstructions and representative cross sections through lesions.

On the basis of these results degeneration of the n. medialis dorsalis pars parvicellularis is correlated with anterior and lateral orbital lesions; of the pars magnocellularis with ablations of the rostral portions of the posterior orbital gyrus; of n. medialis ventralis (reuniens) with the temporal polar and amygdaloid formations; of the remaining midline and intralaminar nuclei with the most posterior and medial portions of orbital cortex, anterior perforate space, and limen insulae; and of the medial pulvinar with the anterolateral temporal cortex.<sup>8</sup>

#### DISCUSSION

Utilizing neuronographic cortical parcellation and a battery of behavioral observations and tests, several categories of behavior have been differentiated from the complex syndrome associated with large bilateral temporal lobe lesions and related to the frontotemporal region. Unaffected by frontotemporal lesions is performance in vision, with respect to acuity, extent of field, and ability to make simultaneous discriminations. Ability to localize tactile stimuli is unimpaired, range of movement unaltered. Performance in the delayed-reaction test is unchanged. On the other hand, altered behavior does occur in the categories of taste, food intake, general activity, and approach to or avoidance of a variety of stimuli including noxious and social ones. This specificity of results takes on added significance in light of the fact that ablations of adjacent regions of the frontal and temporal lobes have produced a different constellation of behavioral changes: *viz.* ablations in the lateral frontal region are associated with selective interference with delayed-response-type functions; ablations in the medial occipitotemporal region result in selective impairment of animal's ability to solve problems involving visual discrimination.

Postoperatively some animals with frontotemporal lesions ate meat. Some accepted quinine solution of significantly

<sup>8</sup>The authors gratefully acknowledge the help and supervision of Dr. Jerzy Rose and Dr. Kao Liang Chow in the analysis and interpretation of the thalamic degeneration reported in this study.

higher concentration than preoperatively. However, animals with altered thresholds of acceptance for quinine or those with ageusia for quinine did not necessarily eat meat. Furthermore, the variability of the change in taste preference cannot be correlated with variability in size or locus of lesion in the present experiments. Other studies in progress may clarify some of these points.

The studies of Brobeck ('45, '48) and Jones ('43) have related animals' short-term food intake and locomotor activity to the maintenance of body temperature. The results of the present experiments implicate the frontotemporal region in the regulation of basal temperature, sleep-activity cycles, and food intake. A control ablation of the anterior cingulate gyrus failed to produce changes in these functions although, as indicated by the results of electrical stimulation of the cortex (Green and Hoff, '37; Kaada, '51; Kaada, Pribram and Epstein, '49; Smith, '38, '45; Speakman and Babkin, '49; Ward, '48), both of these regions are equally concerned with visceral regulations. The different effects of the two ablations may be due to the fact that the cingulate resection is restricted to cortex while the frontotemporal resection invades the amygdaloid complex and caudate head. It is important to keep in mind that the lesions of the frontotemporal region in the present experiments, as well as those of previous bilateral temporal lobectomies and medial temporal resections, are not strictly comparable to ablations restricted to cortex.

Most difficult to evaluate is the alteration in approach-avoidance behavior which results from interference with the frontotemporal region. In many animals there was no correlation between this change and an altered taste threshold. Correlation is also lacking between this changed approach-avoidance behavior and deficient performance of any of the tests of vision or of delayed reaction. On the other hand, whenever the "hypermetamorphic" reaction to small and glittering objects, lack of persistent avoidance of noxious stimuli, and repetitive approach to other animals were also observed in an animal, changes in food intake and the ab-

activity cycle were noted. It seems, therefore, that changes in the animal's appetitive mechanisms related to the internal regulations and changes in its gross behavior are concomitantly affected. More specific analysis of the mechanisms whereby frontotemporal lesions influence the "hypermetamorphic" reaction and the repetitive approach to noxious stimuli awaits further experiment.

There appears to be some correlation between magnitude of behavioral change and extent of bilateral involvement of the frontotemporal region. The techniques both for measuring this behavioral change and for estimating cerebral mass are crude. It is not clear therefore to what extent such correlation depends, on the one hand, on the mass of tissue removed, and on the other, the particular locus (e.g., posterior nuclei of the amygdala), of the removal. Some information regarding this problem comes, however, from the subtotal resections within the frontotemporal region. These demonstrate that the constellation of symptoms produced by the total lesion can be further analyzed. Lesions of the orbital cortex of the frontal lobe which invade the caudate nucleus invariably produce locomotor hyperactivity (Kennard, Spencer and Fountain, '41; Mettler, '44; Ruch and Shenkin, '43). Although other lesions of the frontal lobe may result in similar change, lesions of the insula and temporal lobe do not (Blum, Chow and Pribram, '50; Davis, '51; Pribram, Mishkin, Rosvold and Kaplan, '52). Ablations in the anterior insular portion of the region can be selectively related to changes in acceptance threshold for quinine but not to change in herbivorous dietary habits. The polar and medial temporal areas, on the other hand, are selectively implicated in the altered approach-avoidance behavior.

Additional evidence from the retrograde thalamic degeneration studies indicates that the frontotemporal region may profitably be subdivided. Only lesions of the frontal portion (posterior orbital gyrus, anterior perforate substance) result in retrograde degeneration of the medial portion of the medio-dorsal nucleus, the midline and medial intralaminar nuclei.



One exception is the degeneration of the nucleus reuniens or medialis ventralis in animal TP following resection of the temporal pole and amygdala. Degeneration in this nucleus has previously been found only from lesions of the subcallosal gyrus in rabbits (Rose and Woolsey, '48). It is difficult to reconcile these data since no known common fiber pathway could be interrupted in both lesions. Further anatomical studies specifically directed toward clarifying this point are necessary to the resolution of this discrepancy. Nor are ablations of the anterior insular cortex sufficiently selective to warrant conclusions regarding thalamic connections. On the other hand, degeneration in the medial pulvinar has previously been correlated with anterior temporal lesions (Chow, '50), and this relationship has been confirmed in the present study whenever the anterolateral temporal cortex was extensively invaded. It thus appears probable that at least the orbital and temporal portions of the frontotemporal region receive projections from different thalamic loci. However, it is also apparent that when lesions are restricted to the hilar portions of the region, thalamic degeneration is limited to the most midline portions of the thalamus.

These considerations implicate the neuronographically defined frontotemporal subdivision of the cerebral hemispheres in mechanisms regulating taste and energy metabolism and gross approach-avoidance behavior. Specifically, the frontal portion of the region is related to locomotor activity, the insular portion to taste, the temporal polar-amygdaloid formations to food intake and temperature regulation, and the "hypermetamorphic" behavior described by Klüver and Bucy ('39). Furthermore, these experiments suggest that the frontotemporal region is not implicated in the performance of visual-discrimination or delayed-response-type tasks, despite the fact that interference with such performance has been selectively obtained from lesions of adjacent temporal and frontal cortex respectively.

## SUMMARY

1. Ten subjects, one adult male *Chaema* baboon, one adult female Guinea baboon and 8 immature rhesus macaques were used. One baboon and 5 macaques received extensive bilateral ablations of the frontotemporal region of the cerebral hemispheres as defined in neuronographic studies. The additional animals received lesions restricted to the orbital, insular, and temporal portions of the region. Locus and extent of lesion was verified histologically and reconstructions were made. Thalamic degeneration was analyzed.

2. A battery of observations and tests was administered pre- and postoperatively. This battery included such tests for visual processes as determination of the extent of visual fields, examination of visual pursuit and visual acuity, training for performance of visual pattern discrimination and testing of discrimination of food from non-food objects. Acceptance thresholds for quinine solutions of various concentrations were determined. The response to social and noxious stimuli was recorded. Performance of delayed response was tested. Locomotor activity, food intake, and basal temperature determinations were made, and sleep-activity cycles observed.

3. In general, reconstruction showed lesions to be bilaterally symmetrical and to include most of the cortex of the posterior orbital gyrus, anterior and limen insulae, as well as temporal pole, periamygdaloid cortex and amygdala. Degeneration in the medial magnocellular portion of the n. medialis dorsalis, midline intralaminar, n. medialis ventralis, and medial pulvinar of the thalamus were related respectively to the lesions in the posterior orbital gyrus, anterior perforate substance and limen insulae, temporal polar formations, and antero-lateral temporal cortex.

4. Several aspects of the complex syndrome associated with large bilateral temporal lobe lesions were selectively related to interference with the frontotemporal region. Performance in vision, with respect to acuity, extent of field, and ability to make discriminations was unaffected by such lesions. No changes with respect to ability to localize tactile stimuli were

observed. Range of movement was unaltered. Performance in the delayed-reaction test was unimpaired. On the other hand, altered behavior did occur in the categories of taste, energy metabolism and approach to or avoidance of a variety of stimuli including noxious and social ones.

5. This specificity of results takes on added significance in light of the fact that ablation of adjacent regions of the frontal and temporal lobes have produced a different constellation of behavioral changes. Ablations in the lateral frontal region are associated with selective interference with delayed-response-type functions (Pribram, Mishkin, Rosvold and Kaplan, '52). Inferior temporal ablations result in selective impairment of animal's ability to solve simultaneously presented problems of visual discrimination (Chow, '51; Mishkin, in press; Mishkin and Pribram, in press).

6. Further subdivision of the syndrome is possible by making more restricted lesions in the frontotemporal region. Specifically, the frontal portion of the region is related to locomotor activity, the insular portion to taste, and the temporal polar-amygdaloid formations to food intake and temperature regulation.

7. The relation between altered appetitive mechanisms related to metabolism and altered reaction to noxious and social stimuli is pointed out.

## LITERATURE CITED

- ✓ ADER, H. W., AND D. H. RAAB 1949 Effect of preoccipital and temporal deorientation on learned visual discrimination in monkeys. *J. Neurophysiol.*, 12: 101-108.
- ✓ BAILEY, P., G. VON BONIN, H. W. GAROL AND W. S. McCULLOCH 1943 Functional organization of temporal lobe of monkey (*Macaca mulatta*) and Chimpanzee (*Pan satyrus*). *J. Neurophysiol.*, 6: 121-128.
- ✓ BARD, P., AND V. B. MOUNTCASTLE 1948 Some forebrain mechanisms involved in expression of rage with special reference to suppression of angry behavior. *Res. Publ., A. Nerv. and Ment. Dis.*, 27: 362-404.
- ✓ BIANCHI, L. 1922 *The Mechanism of the Brain and the Function of the Frontal Lobes.* (Trans. by J. H. Macdonald.) William Wood and Co., New York. 248 pp.
- ✓ BLUM, J. S., K. L. CHOW AND K. H. PRIBRAM 1950 A behavioral analysis of the organization of the parieto-temporo-preoccipital cortex. *J. Comp. Neur.*, 93: 53-100.

- BROBECK, J. R. 1945 Effects of variations in activity, food intake and environmental temperature on weight gain in the albino rat. *Am. J. Physiol.*, *142*: 1-5.
- 1948 Food intake as a mechanism of temperature regulation. *Yale J. Biol. and Med.*, *29*: 545-552.
- BROWN, S., AND E. A. SCHÄFER 1888 An investigation into the functions of the occipital and temporal lobes of the monkey's brain. *Phil. Trans. Roy. Soc. London*, *179B*: 303-327.
- CHOW, K. L. 1950 A retrograde cell degeneration study of the cortical projection field of the pulvinar in the monkey. *J. Comp. Neur.*, *93*: 313-340.
- 1951 Effects of partial extirpations of the posterior association cortex on visually mediated behavior in monkeys. *Comp. Psychol. Monogr.*, *29*: 187-217.
- DAVIS, G. D. 1951 Locomotor Hyperactivity Induced by Cerebral Lesions in the Monkey. Unpublished Ph.D. Dissertation, Yale Univ.
- GLEES, P., J. COLE, C. W. M. WHITTY AND H. CAIRNS 1950 The effects of lesions in the cingulate gyrus and adjacent areas in monkeys. *J. Neur., Neurosurg. and Psychiat.*, *13*: 178-190.
- GREEN, H. D., AND E. C. HOFF 1937 Effects of faradic stimulation of the cerebral cortex on limb and renal volumes in the cat and monkey. *Am. J. Physiol.*, *118*: 641-658.
- JONES, M. R. 1943 Effect of phenobarbital on food and water intake, activity and weight gain in the white rat. *J. Comp. Psychol.*, *35*: 1-10.
- KAADA, B. R. 1951 Somato-motor, autonomic and electrocorticographic responses to electrical stimulation of "rhinencephalic" and other structures in primates, cat and dog. *Acta Physiol. Scandinavica*, *23*: i-vi, 285 pp.
- KAADA, B. R., K. H. PRIBRAM AND J. A. EPSTEIN 1949 Respiratory and vascular responses in monkeys from temporal pole, insula, orbital surface and cingulate gyrus. A preliminary report. *J. Neurophysiol.*, *12*: 347-356.
- KENSARD, M. A., S. SPENCER AND G. FOUNTAIN, JR. 1941 Hyperactivity in monkeys following lesions of the frontal lobes. *J. Neurophysiol.*, *4*: 512-524.
- KLEVER, H. 1951 *Cerebral Mechanisms in Behavior*. Ed. by L. A. Jeffress. John Wiley and Sons, New York. pp. 147-199.
- KLEVER, H., AND P. C. BUCY 1937 "Psychic blindness" and other symptoms following bilateral temporal lobectomy in rhesus monkeys. *Am. J. Physiol.*, *119*: 352-353.
- 1938 An analysis of certain effects of bilateral temporal lobectomy in the rhesus monkey, with special reference to "psychic blindness." *J. Psychol.*, *5*: 33-54.
- 1939 Preliminary analysis of functions of the temporal lobes in monkeys. *Arch. Neur. and Psychiat.*, *42*: 979-1000.
- MCCULLOCH, W. S. 1934 The functional organization of the cerebral cortex. *Physiol. Rev.*, *14*: 390-407.
- MERRILL, F. A. 1944 Physiologic effects of bilateral simultaneous frontal lesions in the primate. *J. Comp. Neur.*, *81*: 105-132.
- MISKIN, M. 1952 Visual discrimination performance following partial ablations of the temporal lobe: I. Ventral vs lateral. *J. Comp. Physiol. Psychol.*, *2*: 1-10.

- MISHKIN, M., AND K. H. PRIBRAM 1953 Visual discrimination performance following partial ablations of the temporal lobe: II. Ventral surface vs hippocampus. *J. Comp. Physiol. Psychol.* (in press).
- PATTON, H. D., AND T. C. RUCH 1944 Preference thresholds for quinine hydrochloride in chimpanzee, monkey, and rat. *J. Comp. Psychol.*, 57: 35-49.
- PETE, R., L. B. HOLDEN AND J. JIROUT 1949 The efferent intercortical connections of the superficial cortex of the temporal lobe (*Macaca mulatta*). *J. Neurophysiol.*, 12: 100-103.
- PRIBRAM, K. H., M. A. DENNON AND R. H. DUNSMORE 1950 Some connections of the orbito-fronto-temporal, limbic and hippocampal areas of *Macaca mulatta*. *J. Neurophysiol.*, 13: 127-135.
- PRIBRAM, K. H., AND P. D. MACLEAN 1953 A neurographic analysis of the medial and basal cerebral cortex comparing cat and monkey: monkey. *J. Neurophysiol.*, 16: 324-340.
- PRIBRAM, K. H., M. MISHKIN, H. E. ROSVOLD AND S. J. KAPLAN 1952 Effects on delayed response performance of lesions of dorsolateral and ventromedial frontal cortex of baboons. *J. Comp. Psychol.*, 45: 565-575.
- RIOPELLE, A. J., H. F. HARLOW, P. H. SETTLAGE AND H. W. ADES 1951 Performance of normal and operated monkeys on visual learning tests. *J. Comp. Psychol.*, 44: 283-289.
- ROSE, J. E., AND C. N. WOOLSEY 1948 Structure and relations of limbic cortex and anterior thalamic nuclei in rabbit and cat. *J. Comp. Neurol.*, 59: 279-348.
- RUCH, T. C., AND H. A. SHENKIN 1943 The relation of area 13 on orbital surface of frontal lobes to hyperactivity and hyperphagia in monkeys. *J. Neurophysiol.*, 6: 349-360.
- SMITH, W. K. 1938 The representation of respiratory movements in the cerebral cortex. *J. Neurophysiol.*, 1: 55-68.
- 1945 The functional significance of the rostral cingular cortex as revealed by its response to electrical stimulation. *J. Neurophysiol.*, 8: 241-256.
- SPEAKMAN, T. J., AND B. P. BABKIN 1949 Effect of cortical stimulation on respiratory rate. *Am. J. Physiol.*, 159: 239-246.
- SUGAR, O., J. D. FRENCH AND J. G. CHUSID 1948 Corticocortical connections of the superior surface of the temporal operculum in the monkey (*Macaca mulatta*). *J. Neurophysiol.*, 11: 175-184.
- THOMSON, A. P., AND A. E. WALKER 1950 Behavioral alterations following lesions of the medial surface of the temporal lobe. *Folia psychiat. neurol. et neurochir. uerl.*, 53: 444-452.
- WARD, A. A., JR. 1948 The cingular gyrus: area 24. *J. Neurophysiol.*, 11: 13-23.